Cannula Versus Sharp Needle for Placement of Soft Tissue Fillers: An Observational Cadaver Study

Aesthetic Surgery Journal
2018, Vol 38(1) 73–88

DOI: 10.1093/asj/sjw220
www.aestheticsurgeryjournal.com
OXFORD UNIVERSITY PRESS

Jani A. J. van Loghem, MD; Dalvi Humzah, MD, FRCS (Plast); and Martina Kerscher, MD, PhD

Abstract

Background: Soft-tissue fillers have become important products for facial rejuvenation. Deep fat compartments and facial bones lose volume during the natural aging process. For the most natural-looking results, deep volumetric injections at strategic sites are therefore preferred. Supraperiosteal placement is performed with a sharp needle or a non-traumatic cannula.

Objectives: The primary objective was to determine whether there is a difference in precision between supraperiosteal placement with a sharp needle compared with a non-traumatic cannula in cadaver specimens. A secondary objective was to analyze the safety profiles of both injection techniques.

Methods: Cadaver heads were injected with dye material and soft-tissue fillers at multiple aesthetic facial sites on the supraperiosteum and subsequently dissected for observation of dye and filler placement.

Results: The non-traumatic cannula technique resulted in product being confined to the deep anatomic layers. In contrast, with the sharp needle technique, material was placed in multiple anatomic layers, from the periosteum to more superficial skin layers. For both techniques results were consistent for all facial sites.

Conclusions: Although direct extrapolation from cadavers to the in vivo situation cannot be made, cannulae showed more precision in placement of product. With the sharp needle, the material was injected on the periosteum, and then migrated in a retrograde direction along the trajectory of the needle path, ending up in multiple anatomic layers. The sharp needle technique also showed a higher complication risk with intra-arterial injection occurring, even though the needle tip was positioned on the periosteum and the product was injected with the needle in constant contact with the periosteum.

Editorial Decision date: October 17, 2016; online publish-ahead-of-print December 15, 2016.

In a market where patients are less willing to undergo considerable downtime and do not want a major surgical procedure, the demand for soft-tissue fillers is increasing.[1,2] According to data from the American Society for Aesthetic Plastic Surgery (ASAPS), more than 2.1 million hyaluronic acid filler treatments were performed in 2015, making them the second most popular nonsurgical cosmetic procedure performed in the United States after neuromodulators; the latter procedure is frequently performed in concert with soft-tissue filler injections.[3]

At the forefront of developments in aesthetic medicine, physicians have advanced beyond filling rhytides and are now targeting specific facial sites for deep volumetric augmentation.[4,5] Evidence for significant volume loss in specific deep fat compartments and facial bones during the aging process is well documented in the medical literature.[6-8] The aging process occurs in all anatomical layers of the face and rejuvenation should therefore not

Dr van Loghem is an aesthetic physician in private practice in Amsterdam, Netherlands. Dr Humzah is a Consultant Plastic Surgeon, West Midlands Hospital, Halesowen, West Midlands, United Kingdom. Prof Kerscher is a Dermatologist and Clinical Professor, Department of Chemistry, University of Hamburg, Hamburg, Germany.

Corresponding Author:
Dr Jani van Loghem, Doctors Inc., Falckstraat 51, 1017 VV Amsterdam, the Netherlands.
E-mail: jani@doctors-inc.com

be limited to dermal signs of aging.[7] Injection of fillers at strategic target sites can reconstruct a youthful anatomy and thereby provide the patient with a natural result.[8] As the relatively new field of aesthetic medicine develops, practitioners are using filler products and techniques with established safety profiles to reduce complications and to increase patient satisfaction.[9] To provide natural-looking results, the physician must have a thorough knowledge of the anatomical changes taking place during the aging process and be able to place fillers in the specific target areas that have lost volume.[10,11] The practitioner should also be aware of the key anatomical features of each injection site and choose an injection technique that is safe and effective.[12-14]

The facial arterial system in particular, represents a danger zone for filler injections, as intra-arterial injection can potentially lead to widespread necrosis and even blindness.[13-15] Blindness can occur by injection in an artery in proximity to the orbit and requires rapid specialist intervention. Minimizing the risk of intra-arterial injection of fillers is therefore of paramount importance.[14,15]

Technological developments include the introduction of the blunt-tipped, or non-traumatic cannula as an alternative to the sharp needle. With a sharp needle, placement of the needle tip is considered very precise. It is therefore assumed that positioning the tip at the periosteum is relatively easy and will result in precise placement of filler product.[16] However, final placement of the filler at this level cannot be guaranteed.

Treatment with non-traumatic cannulae results in significantly fewer bruises and lower pain scores, and is gaining in popularity.[17] However, non-traumatic cannulae are more difficult to manoeuvre to the periosteal level and cannula techniques are therefore wrongly regarded as less precise than those using a needle. Placing the tip of a sharp needle on the periosteum is often thought to be a safe technique to avoid intra-vascular embolization for two main reasons. First, there are very few arteries running over the periosteum, making it almost an avascular area. Second, it is assumed that a needle with an artery in its trajectory, will completely pierce the artery and exit the other side, avoiding injection of product in the lumen of the artery.

In this cadaver dissection study, our aim was to determine the final position of injected product using sharp needle vs non-traumatic cannula techniques in a split-face approach. A secondary aim was to study the safety profiles of both injection techniques, related to adjacent arterial danger zones.

METHODS

To assess current opinion concerning the safety and precision of needles vs cannulae and to determine which needle and cannula injection techniques are used most frequently, a poll of expert injectors (plastic surgeons, dermatologists, and aesthetic physicians) was conducted. Injectors were recruited from the personal contacts of one of the authors (JvL) and asked to complete a web-based questionnaire. Using the FSQM Pro WordPress plugin, the entries were stored in a database and analyzed. The online poll was left open for 7 days before downloading the results.

Two thawed, previously frozen, unembalmed cadaver heads (one male, 85 years old and one female, 92 years old) were provided for a single day dissection study in March 2015 by the Skills Lab of the Academic Medical Center in Amsterdam (consent for the use of still images for this article was provided by the department of Anatomy, Embryology and Physiology; consent for the use of recorded video was only provided for offline use at congresses and scientific meetings). The individuals had consented to the scientific and medical use of their bodies prior to their deaths.

The following aesthetic indication sites were marked: frontal concavity, temporal hollows, tear troughs, the lateral mandible, and the mentum. The marked areas were injected with either a non-traumatic cannula (25G, 50 mm Steriglide, TSK Laboratory, Japan) with retrograde treads, or a short, sharp needle (25G, 25 mm, Terumo, Belgium). A longer sharp needle was used when tissue thickness demanded this (27G, 40 mm, Terumo, Belgium). With the sharp needle, a supraperiosteal bolus technique was used. This involved positioning the needle tip perpendicular (60-90 degrees) to the skin, advancing until there was direct contact with the periosteum, and then injecting the material with the needle remaining in direct contact with the periosteum. No hydro-dissection with saline or lidocaine was performed at the supraperiosteal level prior to injection.

To facilitate passage of the non-traumatic, blunt cannula through the dermis, an opening was first made using a 23G sharp needle. In one area (temporal hollows), a thicker gauge needle was used (20G) to make the pre-hole, as this made it easier to pass through the deep temporal fascia. With this technique the cannula was inserted into the tissue at an oblique angle to the skin (10-45 degrees). The injections were performed by two of the authors (JvL and DH). The aim of both techniques was to place colored acrylic dye (Royal Talens, Apeldoorn, Netherlands) on the periosteum, avoiding adjacent danger zones. After injection, the aesthetic zone was lightly massaged and dissected (DH) layer by layer to determine whether any product was present in more superficial layers, and whether any product was in or near an arterial danger zone. To minimize spread of the colored material by mechanical effects of the dissection, a careful layer-by layer dissection was performed

from superficial to deep, without putting any pressure on the tissue. The chosen dye was thick and paste-like and therefor had less tendency to accidentally contaminate the adjacent areas during the dissection, than more liquid colored alternatives.

The first cadaver dissection session was recorded on high-definition video from which high-quality still images were obtained. The final edit took 3 weeks to complete at which point the authors could review the video recordings and export the still images. Two of the authors were then asked to individually determine in which anatomical layers the dye was observed. The layers in which the dye was observed were determined for each instrument and the results were pooled for the two observing physicians to determine whether there was any statistical difference between the two groups (sharp needle/perpendicular approach vs blunt cannula/oblique approach). The Pearson Chi-squared test and Fisher's Exact Test for Count Data (R Studio) were used for statistical analysis. Results of additional cadaver work (with commercially available fillers) were compared and then included in the statistical analysis.

Frontal Concavity, Sharp Needle Technique

The needle was directly advanced to the periosteum of the frontal bone, perpendicular to the skin. With the tip of the needle in direct and constant contact with the periosteum, a bolus of approximately 0.1 mL was slowly injected. The needle was then withdrawn and reintroduced approximately 1 cm further along where additional injections of the same volume were injected in the same manner, totaling approximately 0.5 mL (Figure 1A and 1B).

Frontal Concavity, Non-Traumatic Cannula Technique

The cannula was introduced from the temporal crest through an opening in the skin that was made with a 23G needle. The skin and muscle in front of the cannula were elevated to create a path of least resistance toward the deep anatomical layers. To pass the resistance of the

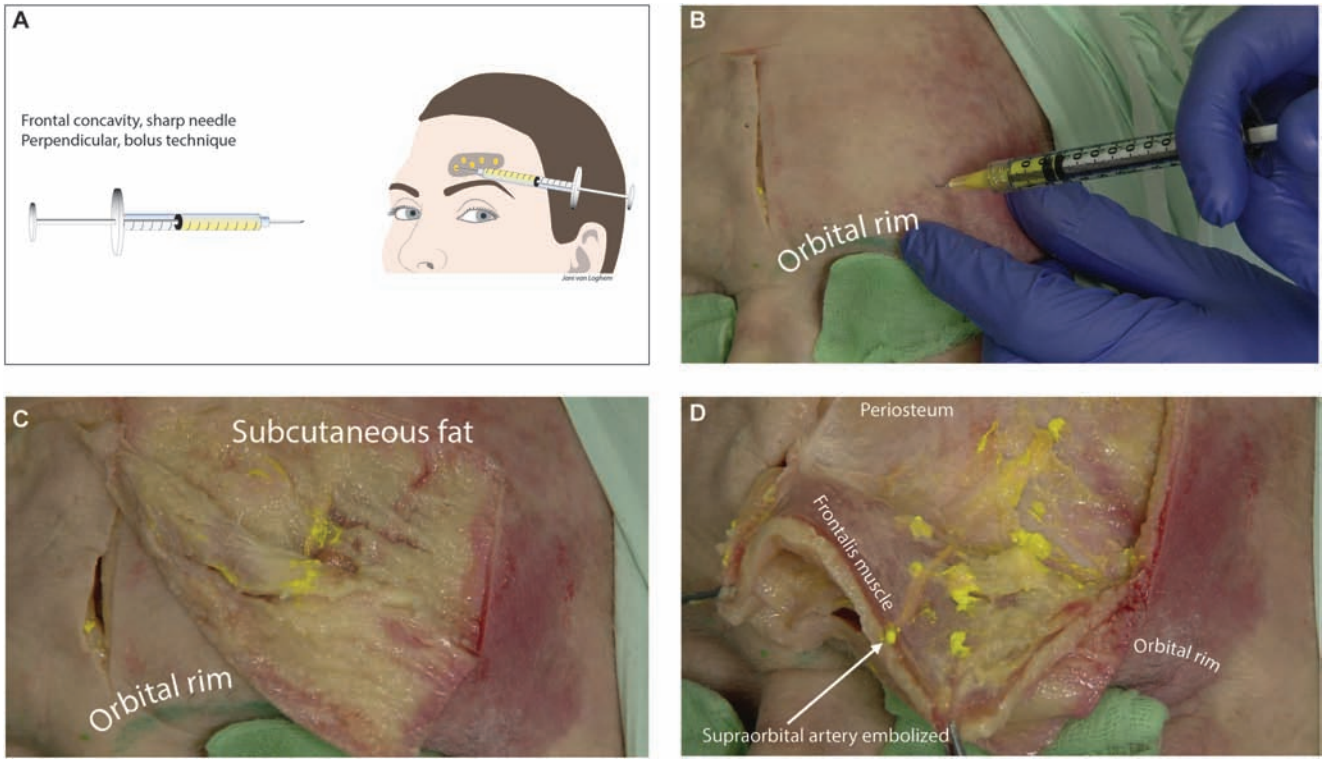

Figure 1. Frontal concavity injected with sharp needle demonstrated on an 85-year-old male cadaver. (A) Schematic diagram of supraperiosteal injection technique. The 25G sharp needle was advanced directly to the periosteum perpendicular to the skin. Multiple boluses were injected with the needle in constant contact with the periosteum. A total of approximately 0.5 mL yellow dye was injected at that level. (B) Overview image of cadaver injection. (C) Subcutaneous view (skin resected). Note the presence of dye (yellow) superficially. (D) Periosteal view (frontalis muscle everted). Note the lumpy appearance of the yellow dye and the accidental intra-vascular injection in the supraorbital artery (white arrow).

galea aponeurotica, the cannula was rotated with a fast rotation of the syringe between the fingers of the injector (rotating technique). After passing this resistance, the injector assumed that the cannula was placed in the glide space between the periosteum and the galea and advanced the cannula at the subgaleal level. Multiple small deposits totaling approximately 0.5 mL were injected in a retrograde fanning technique and lightly massaged after injection (Figure 2A and 2B).

Temporal Hollows, Sharp Needle Technique

The needle was advanced directly to the periosteum of the temporal area at the point of maximum depression, perpendicular to the skin. With the needle tip touching the periosteum, small boluses of approximately 0.1 mL were injected with low pressure. After injection of one bolus, the needle was partly retracted, without exiting the skin, reoriented and readvanced to the periosteum, approximately 5 mm away from the previous injection site. The total volume injected was approximately 0.5 mL (Figure 3A and 3B).

Temporal Hollows, Non-Traumatic Cannula Technique

The cannula was introduced from the lateral side of the temporal crest through an opening in the skin and both temporal fascias made with a 20G needle. After passing the fascia, the injector assumed that the cannula was positioned at the periosteum and advanced the cannula at the submuscular level. Small, retrograde, linear threads totaling approximately 0.5 mL were then injected using a fanning technique followed by light massage (Figure 4A and 4B).

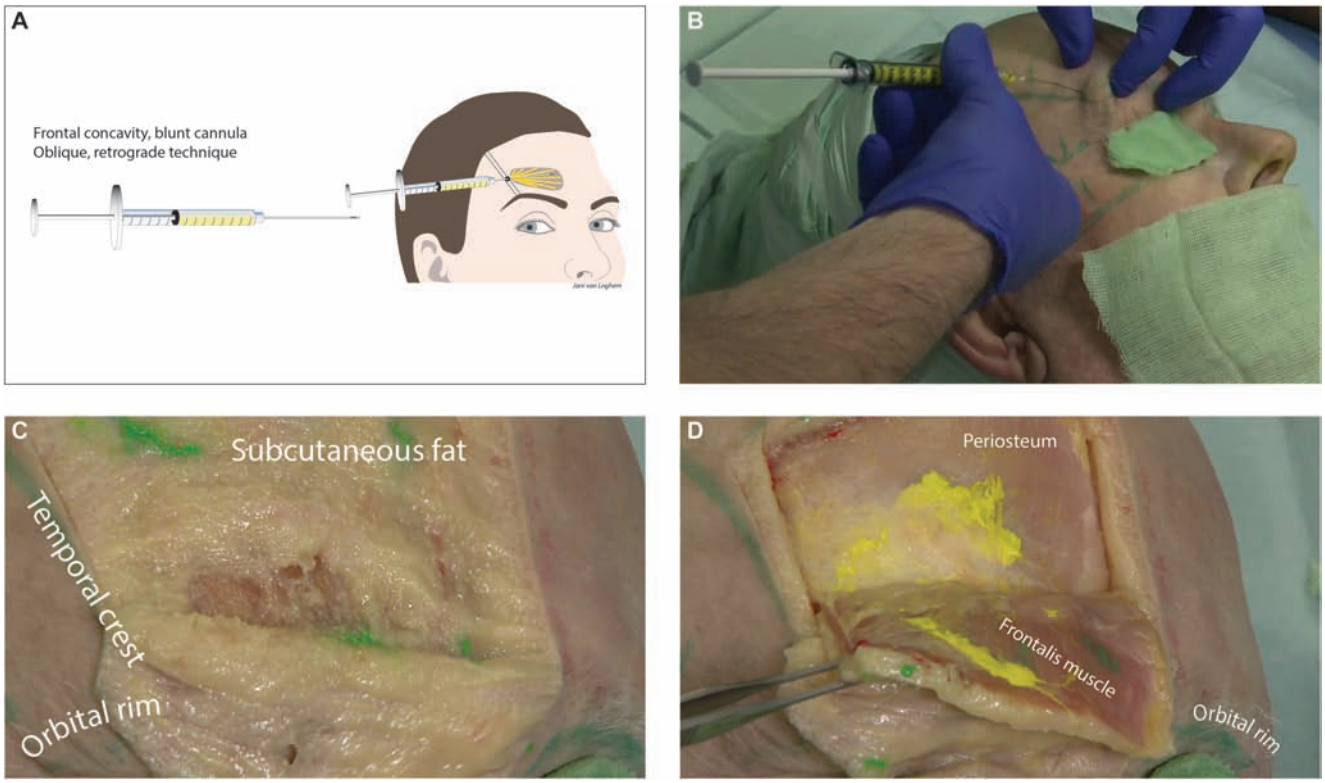

Figure 2. Frontal concavity injected with blunt cannula demonstrated on an 85-year-old male cadaver. (A) Schematic diagram of supraperiosteal injection technique. The 25G blunt cannula was advanced directly to the periosteum through a pre-hole in the skin that was made with a 23G needle at the temporal crest. The cannula was then obliquely advanced through the skin, the galea aponeurotica and the frontalis muscle to the glide space over the periosteum. Multiple retrograde linear threads of yellow dye were injected on the periosteum in a fanning pattern. A total of approximately 0.5 mL was injected at that level. (B) Overview image of cadaver injection. (C) Subcutaneous view (skin resected). No dye was observed at this level. (D) Periosteal view (frontalis muscle everted). Dye (yellow) is placed more evenly and is mostly confined to the glide space between the periosteum and the galea aponeurotica. One small deposit of yellow dye was found in the submuscular layer, no dye was found intramuscularly or more superficially. (Green dye was used for other observations that are not relevant to this study).

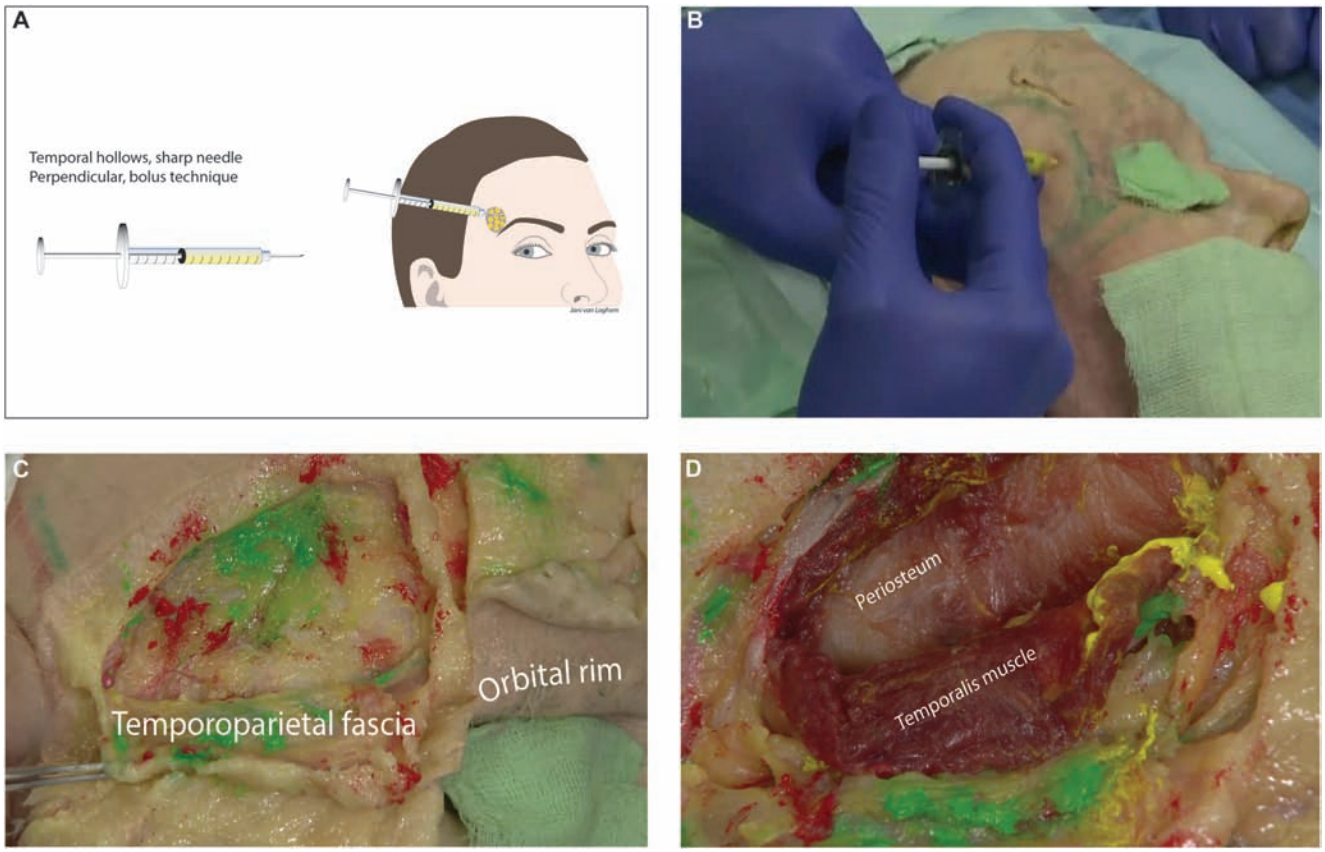

Figure 3. Temporal hollow injected with sharp needle demonstrated on an 85-year-old male cadaver. (A) Schematic diagram of supraperiosteal injection technique. The 25G sharp needle was advanced directly to the periosteum perpendicular to the skin. Multiple boluses were injected with the needle in constant contact with the periosteum. A total of approximately 0.5 mL yellow dye was injected at that level. (B) Overview image of cadaver injection. (C) View of the deep temporal fat (skin and superficial fascia everted). No yellow dye was observed at this depth (green and red colored dyes were injected at more superficial levels and are not the subject of this study). (D) Periosteal view (temporal muscle everted). Almost all yellow dye was located intramuscularly. (Green and red dyes were used for other observations and are not relevant to this study).

Temporal Hollow, Long Sharp Needle Oblique Technique

To assess the possibility that the difference between needle and cannula observations was due to the angle under which the cannula moves through the tissue (oblique vs perpendicular to the skin), we also injected one cadaver in the temporal hollow with a long sharp needle (27G, 40 mm), using the same trajectory as in the cannula technique. The 27G (40 mm) sharp needle was advanced directly to the periosteum with an oblique angle to the skin. As soon as the needle tip made contact with the periosteum, the needle was advanced over the periosteum. Multiple retrograde linear threads were injected with the needle in constant contact with the periosteum. A total of approximately 0.3 mL (yellow dye) was injected at this level (Figure 5A and B).

Tear Trough, Sharp Needle Technique

The tear trough was marked between the infraorbital rim and the infraorbital foramen and the needle advanced perpendicular to the skin directly to the periosteum of the tear trough. Small aliquots of dye were injected with the needle in constant contact with the periosteum. In between aliquots, the needle was "walked" over the periosteum a few millimeters adjacent to where the first bolus was injected. In this manner, multiple, small deposits of dye were injected. The skin was penetrated a total of 4 times, and 8 small boluses of approximately 0.05 mL were deposited (Figure 6A and 6B).[18]

Tear Trough, Non-Traumatic Cannula Technique

The cannula was introduced through the skin just lateral to the point where the nasojugal groove crosses the

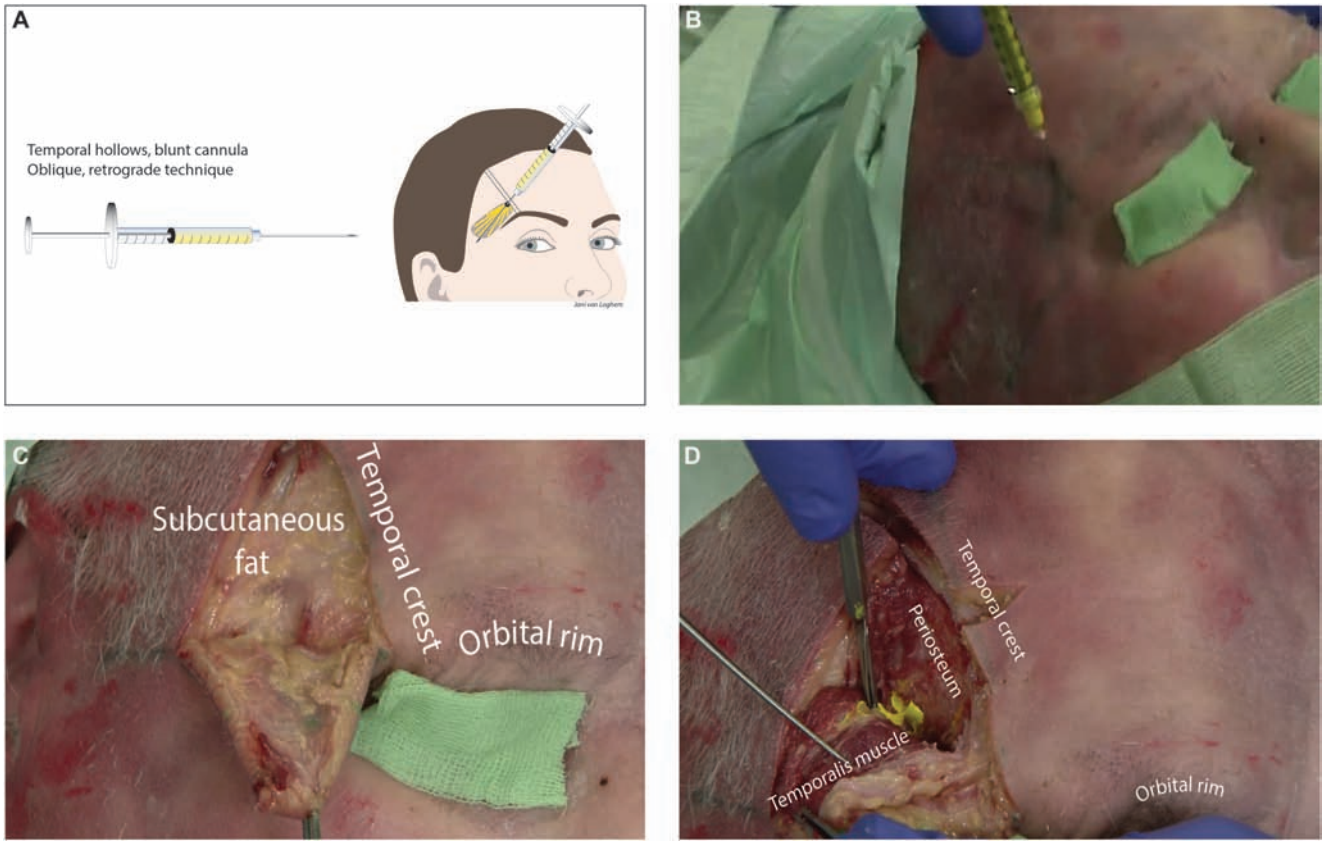

Figure 4. Temporal hollow injected with blunt cannula demonstrated on a 93-year-old female cadaver. (A) Schematic diagram of supraperiosteal injection technique. The 25G blunt cannula was advanced directly to the periosteum through a pre-hole in both the skin and the deep temporal fascia that was made with a 20G needle just lateral to the temporal crest. The cannula was then obliquely advanced through the skin, the deep temporal fascia and the temporalis muscle to the periosteum. Multiple retrograde linear threads were injected on the periosteum in a fanning pattern. A total of approximately 0.5 mL yellow dye was injected at that level. (B) Overview image of cadaver injection. (C) Subcutaneous view (skin resected). No dye was observed at this level or in the deep temporal fat pad. (D) Periosteal view (temporal muscle everted). Dye (yellow) is placed more evenly and is mostly confined to the periosteum. Small deposits were found intramuscularly.

alar-tragal line. It was then advanced obliquely through the skin and the superficial musculo aponeurotic system (SMAS), directly to the periosteum of the tear trough, where retrograde linear threads were injected. A total of approximately 0.2 mL was injected (Figure 7A and 7B).

Lateral Mandible, Sharp Needle Technique

A 27G, 40 mm long needle was inserted perpendicular to the skin and advanced directly to the periosteum of the mandible, medial and cranial to the mandibular angle, deep to the masseter muscle. With the needle tip touching the periosteum, small boluses of approximately 0.1 mL yellow dye were injected with low pressure. After injection of 1 bolus, the needle was partly retracted, without exiting the skin, reoriented and readvanced to the periosteum, approximately 5 mm away from the previous injection site. A total volume of approximately 0.5 mL was injected (Figure 8A and 8B).

Lateral Mandible, Non-Traumatic Cannula Technique

The cannula was inserted through an opening in the skin at the mandibular angle and advanced directly to the periosteum of the mandible, manoeuvring through the resistance of the SMAS and the tendinous attachments of the masseter to the mandible using the rotating technique. Retrograde linear threads of green dye were injected with the cannula moving over the periosteum for a total volume of approximately 0.5 mL (Figure 9A and 9B).

Mentum, Non-Traumatic Cannula Technique

The cannula was inserted through an opening in the skin at the pre-jowl sulcus and advanced directly to the periosteum of the mentum, manoeuvering through any resistance using the rotating technique. Retrograde linear

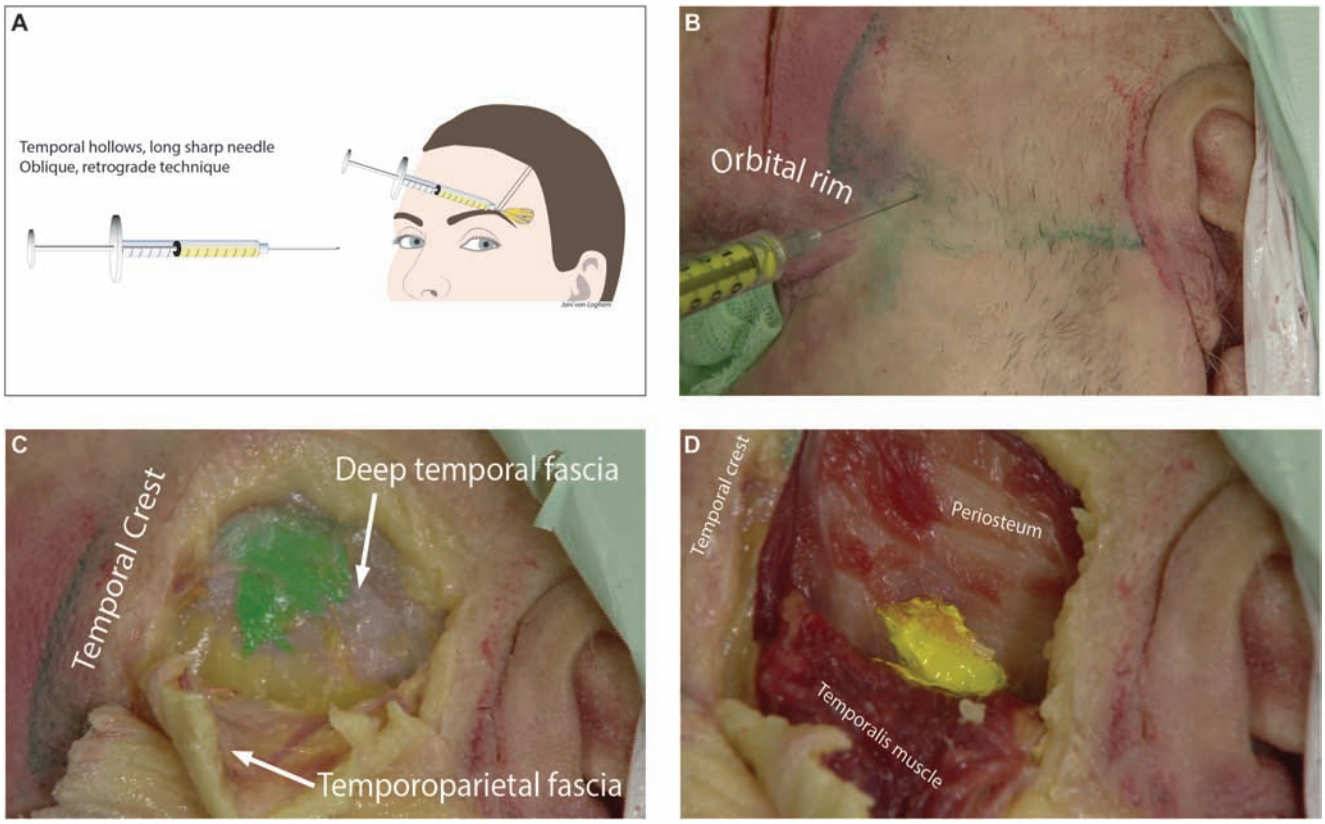

Figure 5. Temporal hollow injected with long sharp needle demonstrated on an 85-year-old male cadaver. (A) Schematic diagram of supraperiosteal injection technique. The 27G (40 mm) sharp needle was advanced directly to the periosteum at an oblique angle to the skin. As soon as the needle tip was in contact with the periosteum, the needle was advanced over the periosteum. Multiple retrograde linear threads were injected with the needle in constant contact with the periosteum. A total of approximately 0.3 mL yellow dye was injected at that level. (B) Overview image of cadaver injection. (C) View of the deep temporal fat (skin and superficial fascia everted). No yellow dye was observed at this depth (green colored dye is not the subject of this study). (D) Periosteal view (temporalis muscle everted). Most dye (yellow) was found located on the periosteum with small amounts intramuscularly.

threads were placed at the periosteal level under the mentalis muscle in retrograde linear threads for a total volume of approximately 0.3 mL (Figure 10A and 10B).

Mentum, Sharp Needle Technique

The needle was inserted perpendicular to the skin and advanced directly to the periosteum of the mentum, just lateral to the midline, below the mentalis muscle. With the needle tip in constant contact with the periosteum, small boluses of approximately 0.1 mL were injected with low pressure. After injection of a bolus, the needle was partly retracted, without exiting the skin, reoriented and readvanced to the periosteum, approximately 5 mm away from the previous injection site. A total volume of approximately 0.3 mL was injected (Figure 11A and 11B).

Additional Cadaver Dissections

Four and eight months after the two initial cadaver dissections had taken place, two of the authors (JvL and DH) performed additional cadaver dissections on two unembalmed cadaver heads (both female, 81 and 78 years old respectively). The second series of dissections used the same needle and cannula injection techniques as before, but injected commercially available fillers. Approval to take photographs in the cadaver laboratory was not available. The fillers were supplied by Merz Aesthetics GmBH (Frankfurt am Main, Germany). The 1 mL syringes of hyaluronic acid (HA) products were mixed with 0.05 mL dye. Calcium hydroxylapatite (CaHA) did not require the addition of a dye because of its existing white color. The following allocation was used for the supraperiosteal placement of the different products: frontal concavity: HA (Belotero Intense); temporal hollows: CaHA (Radiesse); tear troughs: HA (Belotero Balance); mandible: CaHA (Radiesse) and mentum: CaHA (Radiesse). The two authors recorded their findings (Supplemental Figure 1).

RESULTS

Fifty-eight expert injectors were included in the online poll of whom 77% were aesthetic physicians, 15%

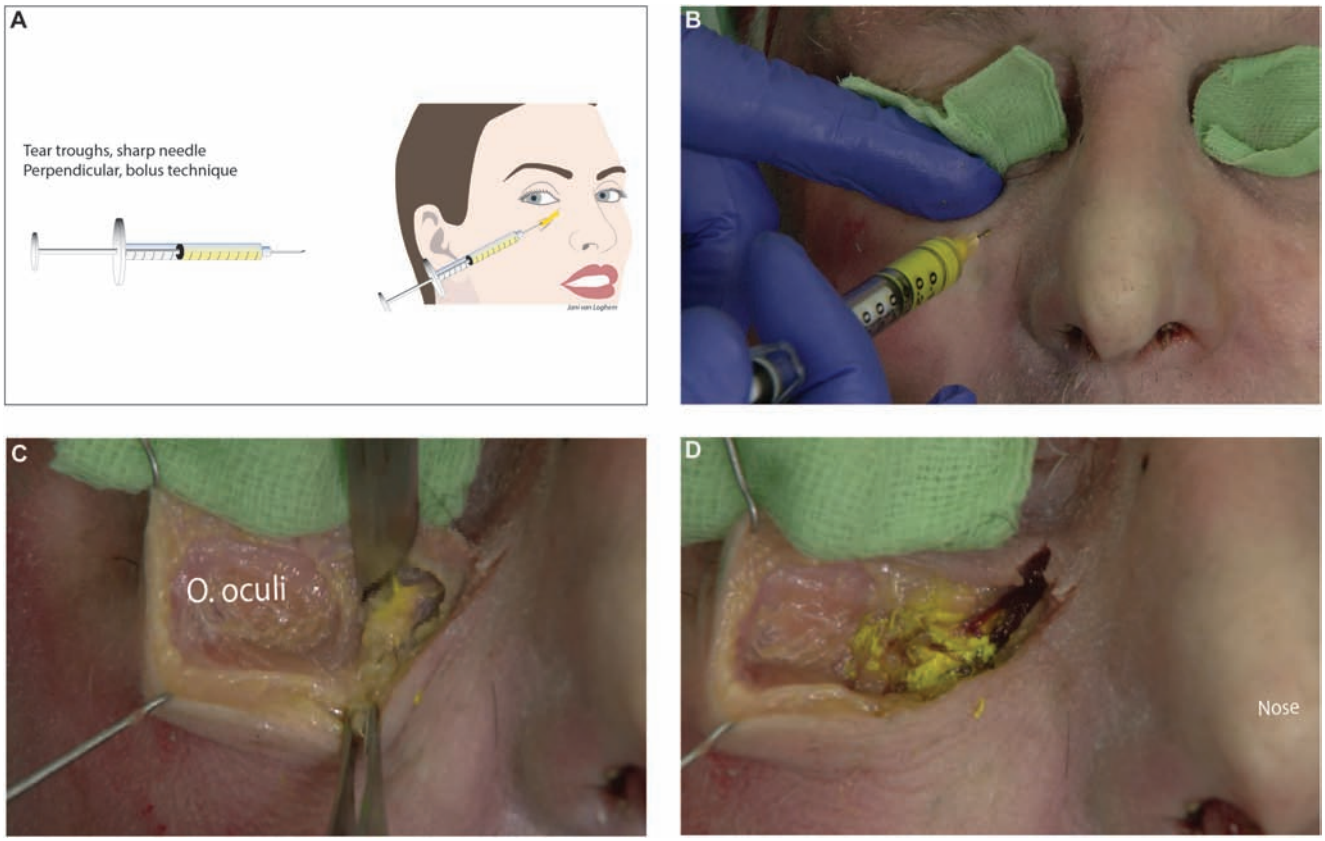

Figure 6. Tear trough injected with sharp needle demonstrated on a 93-year-old female cadaver. (A) Schematic diagram of supraperiosteal injection technique. The 25G sharp needle was advanced directly to the periosteum perpendicular to the skin. Multiple boluses were injected with the needle in constant contact with the periosteum. A total of approximately 0.2 mL yellow dye was injected at that level. (B) Overview image of cadaver injection. (C) Subcutaneous view (skin resected). Note the presence of yellow dye at this superficial level. (D) Periosteal view (orbicularis oculi muscle everted). Dye (yellow) was found in all layers; on the periosteum, intramuscularly and subcutaneously in contact with the skin.

dermatologists, and 2% plastic surgeons. Needles were thought to be more precise for placing a filler at the periosteum by 79% of consulted physicians, whereas 21% believed cannulae were more precise; 71% of the consulted experts agreed that cannulae are safer than needles for injecting fillers at the periosteum. Most experts (79%) used a perpendicular approach when using sharp needles to place fillers on the periosteum, whereas an oblique approach was used by 76% of experts when using non-traumatic cannulae to place fillers on the periosteum.

In the initial cadaver dissections all facial sites consistently showed that the sharp needle technique with the needle perpendicular to the skin, resulted in product being placed at multiple anatomic layers, from the periosteum to more superficial layers, and occasionally ending up at the subdermal and dermal levels. The non-traumatic cannula technique resulted in product being confined to significantly fewer anatomic layers (Supplemental Figure 1).

Frontal Concavity, Sharp Needle Technique

When the skin was dissected, dye was observed in the subcutaneous fat (Figure 1C) in contact with the skin. When the frontalis muscle was resected, product was found intramuscularly, in the galea aponeurotica and on the periosteum (Figure 1D). It was noted that the product was placed unevenly. Of greater concern was that even though the needle tip had been in constant contact with the periosteum on injection, intra-vascular injection of the lateral branch of the supraorbital artery had occurred (Figure 1D, white arrow).

Frontal Concavity, Non-Traumatic Cannula Technique

On dissection, almost all of the injected dye was found to be confined to the submuscular level. No product was found

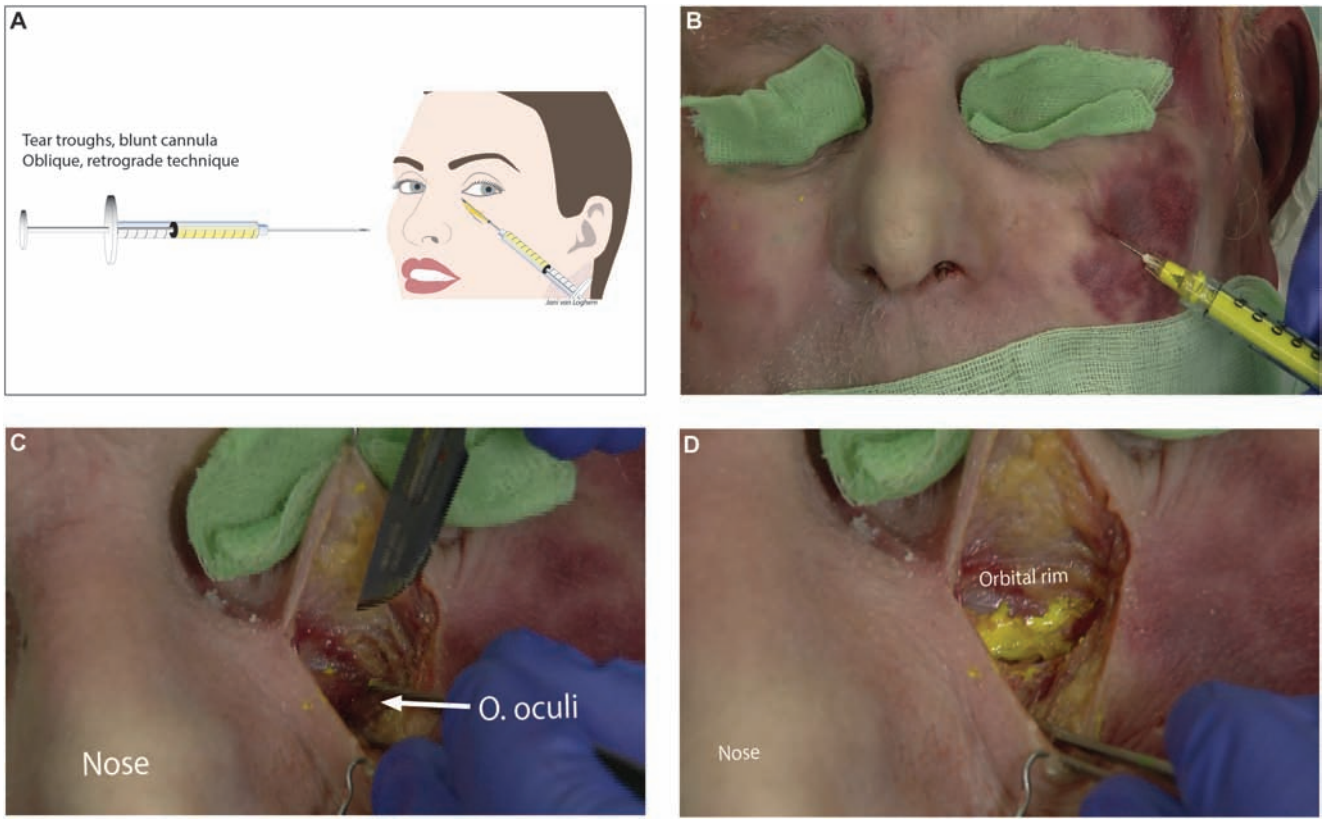

Figure 7. Tear trough injected with blunt cannula demonstrated on a 93-year-old female cadaver. (A) Schematic diagram of supraperiosteal injection technique. The 25G blunt cannula was advanced directly to the periosteum through a pre-hole in the skin that was made with a 23G needle lateral to the skin insertion of the zygomatico cutaneous ligament. The cannula was then obliquely advanced through the skin and the superficial musculo-aponeurotic system to the periosteum. Multiple retrograde linear threads were injected on the periosteum in a fanning pattern. A total of approximately 0.2 mL yellow dye was injected at that level. (B) Overview image of cadaver injection. (C) Subcutaneous view (skin resected). No dye was observed at this level. (D) Periosteal view. Dye (yellow) was found on the periosteum.

intramuscularly or subcutaneously (Figure 2C). Most dye was placed at the periosteum and a small deposit was found inside the galea aponeurotica sub-muscular plane, just deep to the frontalis muscle (Figure 2D). Compared to the sharp needle technique, the dye was placed more evenly.

Temporal Hollows, Sharp Needle Technique

On dissection, no dye was observed subcutaneously or in the deep temporal fat compartment. Most of the dye was observed intramuscularly. Almost no product was observed on the periosteum (Figure 3D).

Temporal Hollows, Non-Traumatic Cannula Technique

On dissection, most of the injected dye was confined to the supraperiosteal, submuscular level. A small amount appeared to be located in the temporalis muscle. No dye was found superficial to the deep part of the muscle (Figure 4C). Compared to the sharp needle technique, the dye was placed more evenly (Figure 4D).

Temporal Hollows, Long Sharp Needle, Oblique Retrograde Technique

On dissection, no dye was observed in superficial layers (Figure 5C). Most of the injected dye was found on the periosteum with a few deposits intramuscularly (Figure 5D).

Tear Trough, Sharp Needle Technique

On dissection, dye was seen in contact with the skin, in the subcutaneous level, in the orbicularis oculi muscle and on the periosteum (Figure 6C and 6D).

Tear Trough, Non-Traumatic Cannula Technique

On dissection, product was seen in contact with the periosteum and not in any other anatomic layer (Figure 7C and 7D).

Figure 8. Mandibular angle injected with sharp needle demonstrated on an 85-year-old male cadaver. (A) Schematic diagram of supraperiosteal injection technique. The 27G, 40 mm long sharp needle was advanced directly to the periosteum perpendicular to the skin. Multiple boluses were injected with the needle in constant contact with the periosteum. A total of approximately 0.5 mL (yellow dye) was injected at that level. (B) Overview image of cadaver injection. (C) Subcutaneous view (skin resected). Note the presence of yellow dye at this level. (D) Periosteal view (masseter muscle is incised). Dye (yellow) was found mostly intramuscularly. Note the proximity of the facial artery (dyed red) to the injected product (white arrow). (Green dye were used for other observations that are not relevant to this study).

Lateral Mandible, Sharp Needle Technique

On dissection, product was observed intramuscularly. Almost no product was observed submuscularly and a minimal amount of dye was observed superficial to the muscle (Figure 8C and 8D).

Lateral Mandible, Non-Traumatic Cannula Technique

On dissection, product was mostly observed in the submuscular plane on the periosteum of the mandible with a small amount injected intramuscularly (Figure 9C and D).

Mentum, Non-Traumatic Cannula Technique

On dissection, product was observed exclusively in the submuscular, supraperiosteal plane (Figure 10C and 10D, yellow dye).

Mentum, Sharp Needle Technique

On dissection, product was observed intramuscularly. Almost no product was observed submuscularly (Figure 11C and 11D, red dye).

Additional Cadaver Dissections

Comparable results were observed when 2 additional cadaver heads were injected with commercially available fillers and dissected. There was no statistical difference in results between the dye and filler dissections. In all the cadaver dissections, the cannula technique consistently resulted in product in fewer anatomic layers than the needle technique. The results of these observations were scored and used for statistical analysis (Supplemental Figure 1).

DISCUSSION

Aesthetic medicine is a relatively young medical field and the available scientific evidence is limited. Best practice

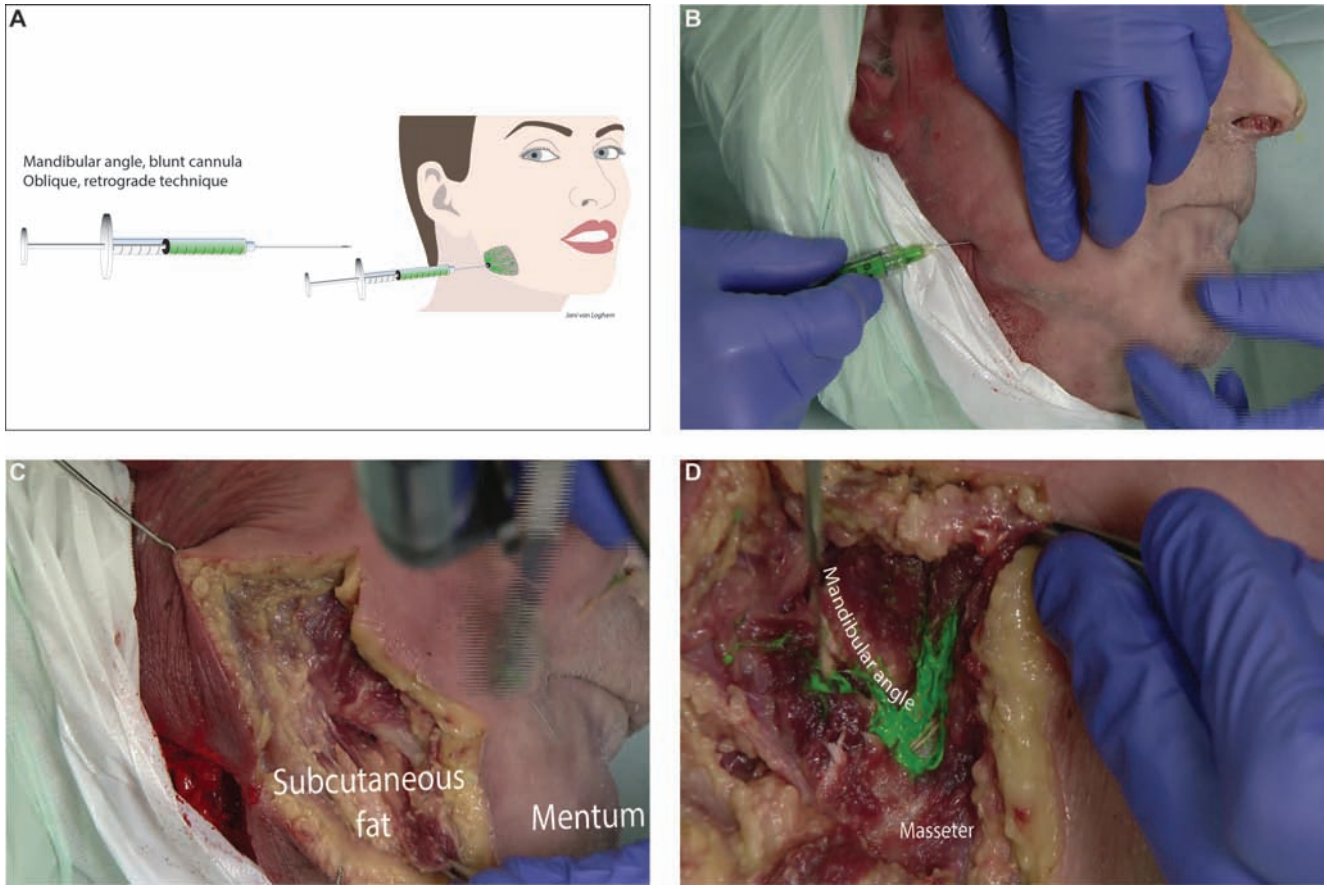

Figure 9. Mandibular angle injected with blunt cannula demonstrated on a 93-year-old female cadaver. (A) Schematic diagram of supraperiosteal injection technique. The 25G blunt cannula was advanced directly to the periosteum through a pre-hole in the skin that was made with a 23G needle at the mandibular angle. The cannula was then obliquely advanced through the skin, advanced through the SMAS and the adhesions of the masseter to the mandible down to the periosteum. Multiple retrograde linear threads were injected on the periosteum in a fanning pattern. A total of approximately 0.5 mL green dye was injected at that level. (B) Overview image of cadaver injection. (C) Subcutaneous view (skin resected). No dye was observed at this level. (D) Periosteal view. Dye (green) was mostly found on the periosteum and some intramuscularly.

techniques are generally learnt from peers at expert meetings and congresses. The introduction and adoption of cannulae to deliver soft-tissue fillers has led to a debate on the use of cannulae over sharp needles.[19] Previously, it had been assumed that the supraperiosteal placement of fillers with a sharp needle was a very precise technique, because of the exact placement of the needle tip. This assumption still represents the majority view, as shown from our poll of expert injectors.

In this observational, cadaver dissection study, we found that the sharp needle technique for periosteal injection of fillers, resulted in product placement not only in the supra-periosteal layer, as was expected, but also in additional anatomic layers, sometimes even as superficial as the subdermis and dermis. The difference in accuracy of filler placement at the preperiosteal level by sharp needles or blunt cannulae can be influenced by multiple factors as summarized in Table 1. We postulate that the most likely reason for the increased product spread with needles is that the material had flowed backward in a retrograde direction through the track of the needle, following the path of least resistance. The needle had been placed on the periosteum via a direct approach perpendicular to the skin, as is common practice, in order to minimize sharp needle associated risks such as bruising and intra-vascular injection. The sharp needle with its beveled point is able to puncture soft tissue layers. However, when the needle tip encounters a hard surface such as bone, the bevel is unlikely to completely penetrate the penultimate layer (eg, epi-mysium) and the product is then injected into the muscle body rather than the supra-periosteal layer; this was a consistent finding in all the areas studied.

To avoid retrograde flow to more superficial layers in clinical practice, an angled instead of perpendicular approach could be considered, as was demonstrated with the long, sharp needle using an oblique pathway. While

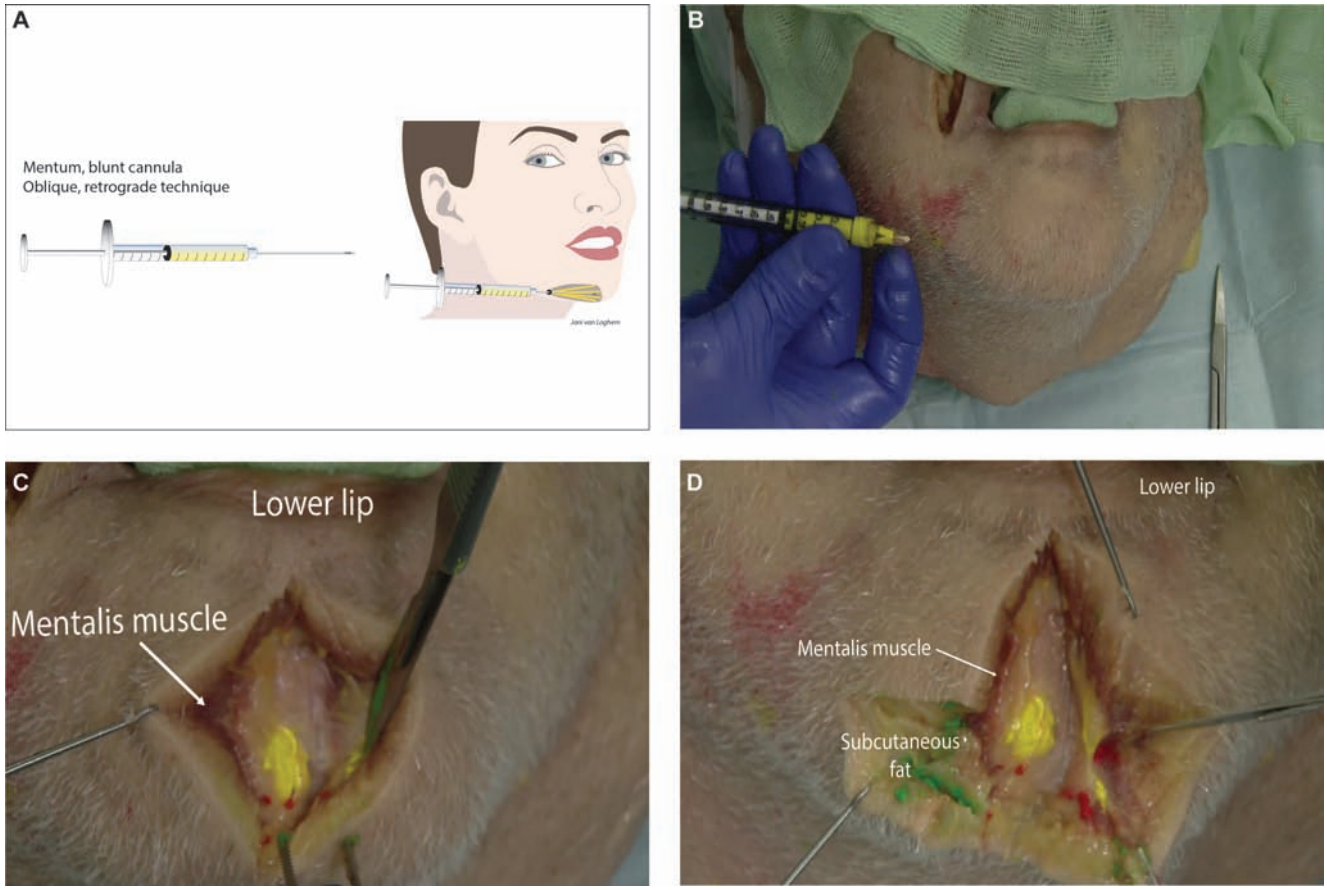

Figure 10. Mentum injected with blunt cannula demonstrated on an 85-year-old male cadaver. (A) Schematic diagram of supraperiosteal injection technique. The 25G blunt cannula was advanced directly to the periosteum through a pre-hole in the skin that was made with a 23G needle at the pre-jowl sulcus. The cannula was then obliquely advanced through the skin, advanced through the depressor labii inferioris muscle to the periosteum of the mandible and then advanced underneath the mentalis muscle. Multiple retrograde linear threads were injected on the periosteum in a fanning pattern. A total of approximately 0.3 mL was injected at that level. (B) Overview image of cadaver injection. (C) No yellow dye was observed in the subcutaneous or muscular levels. (D) Periosteal view. Dye (yellow) was exclusively found on the periosteum (green dye in this image was used for more superficial injection and is not the subject of this study).

such an approach may result in limited product flow to the superficial anatomic layers in vivo, it would pose increased needle-associated risks. In this study, we have established that when a needle was used in an oblique fashion, precision of placement on the periosteum of the temporal hollow was similar to a cannula. However, oblique needle injection might pose more complication risks, as the sharp tip of the needle has a longer path through the tissue, increasing the possibility of the sharp tip damaging an anatomic structure in its trajectory. Theoretically, a perpendicular cannula approach could result in similar results to that seen with needles. We hypothesize that perpendicular use of cannulae will result in even less precise product placement on the periosteum, as the opening of the cannula is not located at the tip, but about 1 to 2 mm proximal to the tip on the side of the cannula. Even if the cannula tip is placed on the periosteum, the filler will be expressed more superficially, potentially not reaching the periosteal level. Perpendicular use of cannulae was not reported by any of the expert injectors that contributed to the poll. The possible bias due to angle of approach is therefore more a theoretical discussion point than a practical one, as in clinical practice the cannula is generally used obliquely and the needle is generally used perpendicularly when injecting on the periosteum.

In clinical practice, hydro-dissection with saline or a local anaesthetic could be considered at the pre-periosteal level to reduce tissue resistance to the filler and therefore limit backflow through the needle trajectory. The disadvantage of this approach is that the injected volume of saline or local anaesthetic will influence the aesthetic baseline prior to injection of filler product. In addition, dilution

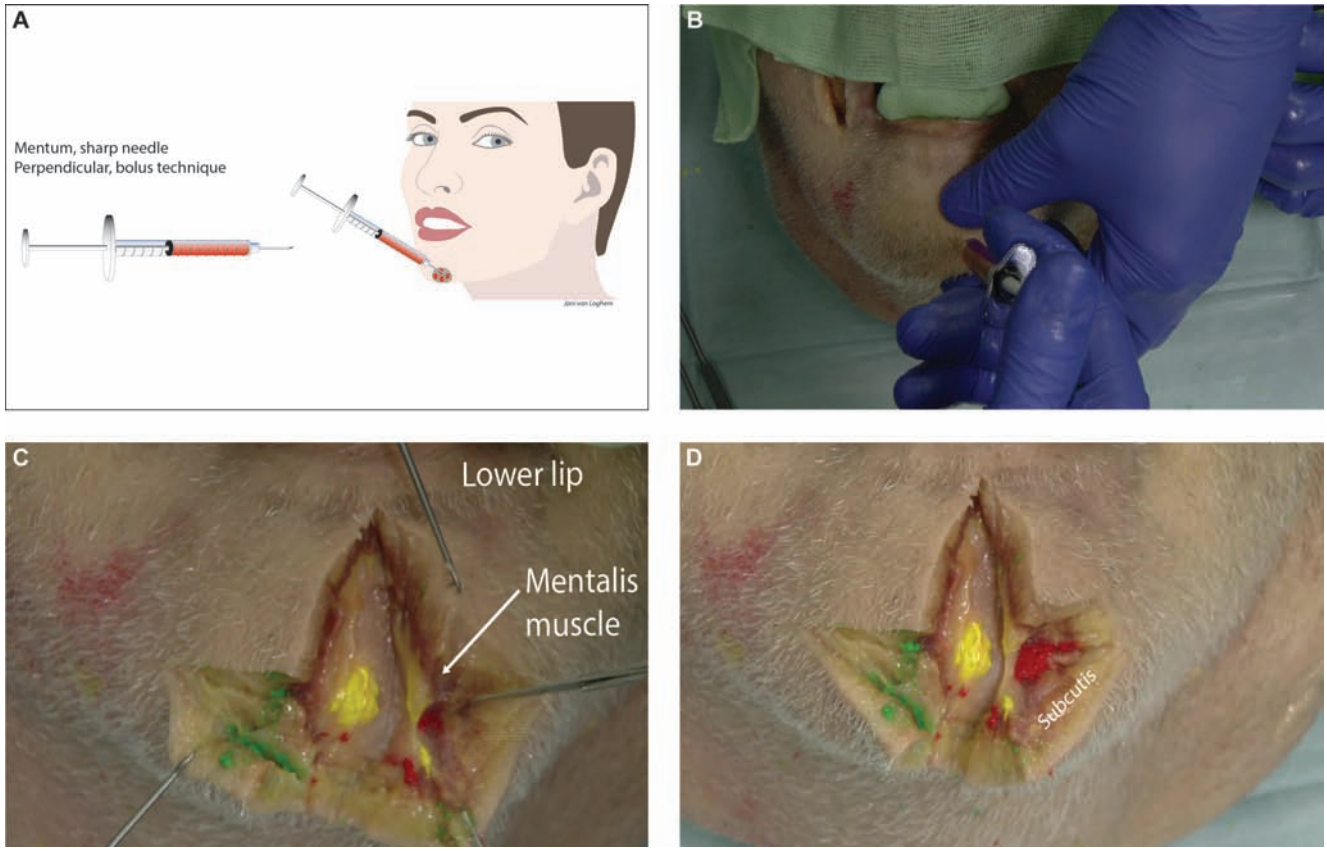

Figure 11. Mentum injected with sharp needle demonstrated on an 85-year-old male cadaver. (A) Schematic diagram of supraperiosteal injection technique. The 25G sharp needle was advanced directly to the periosteum perpendicular to the skin. Multiple boluses were injected with the needle in constant contact with the periosteum. A total of approximately 0.3 mL (red dye) was injected at that level. (B) Overview image of cadaver injection. (C) Red dye was observed inside the mentalis muscle. (D) Periosteal view. Dye (red) was found mostly intramuscularly and some on the periosteum. Note the difference between yellow (cannula) and red (needle) placement of dye (green dye in this image was used for more superficial injection and is not the subject of this study).

of filler with saline or lidocaine might alter the rheologic properties of the injected product. If a practitioner chooses the sharp needle technique for supraperiosteal injection, the depot technique as described by G. Sattler is recommended.[20] With this approach, the tissue is lifted with the non-injecting hand during injection thereby increasing the pressure and thus the resistance in the superficial anatomical layers by the force of the pinching fingers. The technique may therefore be associated with less backflow to the superficial layers, as product will always flow in the direction of least resistance.

The problem of inaccurate filler placement after hyaluronic acid injection at the periosteum with a sharp needle technique has also been reported by Griepentrog et al.[21] They demonstrated histologically that a significant amount of hyaluronic acid gel (Juvéderm, Allergan, Inc., Santa Barbara, CA) did not end up in the intended periosteal plane when injected with a needle in the infra-orbital hollow. Spread of gel to more superficial layers along the needle trajectory might be the reason that malar edema is sometimes seen after needle injection of hyaluronic acid fillers.[1]

In this study, the use of non-traumatic cannulae resulted in a more precise placement of injected material. The dissection results showed the presence of injected product at the targeted supra-periosteal layer with only limited product in the more superficial layer adjacent to the periosteum. Although we can assume that there is also backflow of gel along the trajectory of the cannula, it is likely to be restricted to the same anatomical layer, the periosteum, because of the oblique approach of the cannula.

One drawback of the initial cadaver study is that we used colored acrylic dye to inject, and not commercial fillers. Additional cadaver heads were therefore injected with commercially available fillers to determine whether there were any differences in results based on the rheology of the specific products. Individual gels differ sufficiently in their physical and chemical properties to influence their

Table 1. Possible Factors Influencing Spread Among Tissue Layers

Tissue properties	Cadaver tissue vs live tissue
	• No muscle tonus in cadavers might increase spread
	• Time wasting resulting in friable tissue and increased spread
	• Freezing and thawing might damage tissues and increase spread
	Age of the patient/cadaver: older age may have increased spread due to less dense aged tissues
	Different anatomical layers may have different resistance to product and thereby influence spread:
	• Periosteum (dense)
	• Fat (loose)
	• Muscle (loose along fibers)
	• Fascias (dense)
	• Dermis (dense)
Technique specifics	Angled approach vs perpendicular approach
	• Needle and cannula trajectories represent possible paths of least resistance
	• When the path of least resistance traverses multiple anatomical layers, the chance of backflow to these layers increases
	Lumen of the needle/cannula might influence backflow
	Applied pressure to the syringe might influence backflow positively
Product properties	Rheologic properties influence the amount of spread in the tissue
	• Viscosity
	• Elasticity
	• Cohesivity
	Other product-related factors
	• Particle size
	• Concentration of HA/hydration
	• Crosslinking
	• Temperature

clinical performance. Rheologic properties relevant to the performance of fillers include the degree of cross-linking (in case of hyaluronic acid), cohesivity (the tendency of a gel to stick together and hold its form or shape under stress), gel hardness (G'), gel consistency, viscosity, extrusion force, concentration, and extent of hydration. Differences in the rheologic properties of filler products reflect their specific manufacturing processes and resultant physicochemical characteristics and influence their tissue spread and postulated backflow along the needle

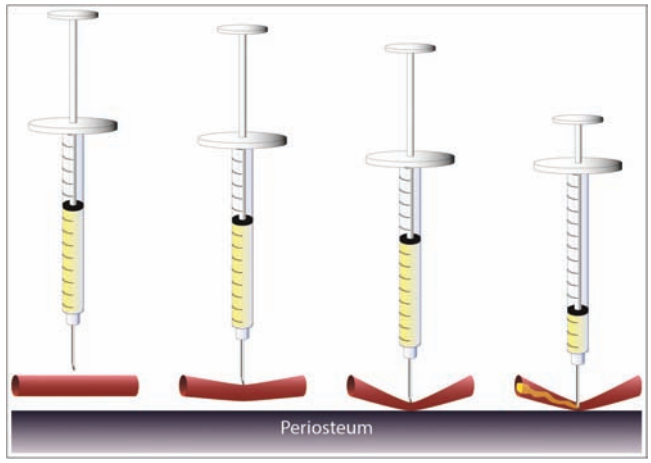

Figure 12. Proposed mechanism of action for the accidental intra-arterial injection that was observed after sharp needle injection in the frontal area. As the needle is advanced to the periosteum, it hits the artery, pushing it down to the bone. At that level, the bevel of the needle penetrates the arterial wall so that the lumen of the needle is in contact with the lumen of the artery. On injection, the dye was injected into the lumen of the artery.

trajectory.[22] Two of the authors therefore performed additional cadaver dissections using commercially available fillers. Results were very similar to the initial cadaver study with no statistical difference between acrylic dye and commercial fillers. This may be explained by the fact that the dissections were performed immediately after injection leaving very little time for the dye to spread. The anatomy of the facial area injected appears to be the defining factor along with the instruments (needle or cannula) and techniques (perpendicular and oblique pathways) used. Other cadaver studies have shown that tissue spread differs with injected substance. For example, CaHA was shown to be confined to the premaxillary space due to its high visco-elastic properties, while a more fluid material spread beyond this semi-open space.[23] Our findings may therefore not be applicable to all filler substances. The diversity of the many filler products on the market with their different rheologic characteristics makes it impossible to give a general conclusion about the extent of retrograde backflow through the needle trajectory, except that a certain amount of backflow is possible. With a perpendicular approach this could mean that the filler may present in multiple anatomic layers.

Our study had several limitations. We used fresh, frozen cadaver heads, and not fresh cadavers. The thawing of the frozen tissues could have adversely affected the normal fascial structures that, in vivo, act as effective barriers. Fresh, frozen cadaver tissue represents a close enough proxy with respect to diffusion and dispersion of drugs, and it was therefore assumed that the tissue

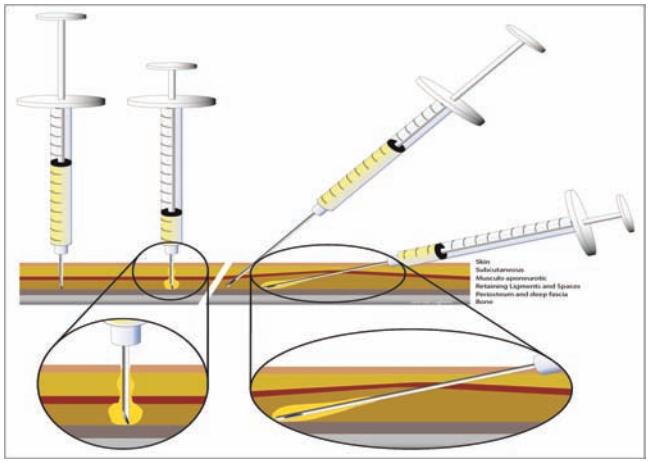

Figure 13. Proposed mechanism of backflow through the trajectory that was made with the sharp needle in a perpendicular direction to the skin and with a blunt cannula that was advanced to the deep layers with an oblique angle. The injected substance will follow the path of least resistance and therefore it is expected to flow back through the trajectory made by the needle or cannula. The needle spans multiple anatomical layers over a shorter distance than the cannula distance and therefore it is expected that with a perpendicular approach, the injected substance will be deposited into more anatomical layers than with a cannula. Note that the cannula technique entails an initial angled descent to the periosteum followed by more horizontal advancement of the cannula at depth (illustrated by the bent tissue layer).

would be a realistic alternative to the in vivo situation as has been established by other workers.[24] The age of the cadavers (85 and 92 years) was not representative of the usual patients requesting filler treatments. Facial anatomy is known to significantly change with age, and most clinical patients are probably in their fourth to sixth decades of life. Future studies with younger cadavers might yield different results. Cadavers have no muscle tonus and therefore we have to accept the possibility that in vivo, there may be a reduced chance of retrograde flow along the needle trajectory. In this study, we only injected with 25G and 27G needles, and 25G cannulae. Even though the outer diameter of the needles and cannulae were known, the lumen diameters were unknown. And therefor, the comparability of the two instruments might be reduced. We however believe that the lumen of the needles and cannulae used in this study are of less significance compared to the angle of the approach, as the expressed product will follow the path of least resistance irrespective of the lumen of the needle or cannula. In common practice, a range of different sized needles and cannulae are used in multiple facial indications. Additional studies might show a difference in results if different gauge needles or cannulae are used.

An important finding was that the lateral branch of the supraorbital artery (deep to the frontalis muscle) was accidentally embolized on injection with the sharp needle technique. The tip of the needle was touching the periosteum during the entire injection and therefore, this study demonstrates that periosteal placement of fillers with a sharp needle can still result in inadvertent intra-vascular injection. We hypothesize that the anterior wall of the artery was penetrated by the needle and the artery then pushed against the bone. In this position, the beveled sharp-needle tip would be unable to penetrate the posterior wall of the artery as the needle will not advance into bone and intra-vascular injection occurred. This possibility should therefore be considered when injecting with a sharp needle on the periosteum (Figure 12).

Statistically, this study could be described as a possible low powered study, because of the low number of included cadavers (four). However, if we recalculate our model for an "IF this than THAT" principle whereby we define five facial areas from two cadavers, multiply by two for both type of injectable materials what were used (dye and fillers were not statistically different) this gives us 20 observations per needle and cannula. With a total of 40 observations, this study shows us a positive and significant result in favor of the blunt cannula.

CONCLUSIONS

A consistent finding in this observational study was that the sharp needle injection technique with a perpendicular approach resulted in dispersal of product into multiple anatomic layers and inconsistent placement in the supra-periosteal layer. The cannula technique with an angled approach was a more accurate method of placing product in the supra-periosteal layer and may be considered a safer procedure.

The same findings were observed in all facial indications studied. The results suggest that using an oblique, angled approach with non-traumatic cannulae results in more precise product placement when targeting a specific anatomic layer with a lower risk of complications.

When injecting with a sharp needle and perpendicular approach, backflow to more superficial anatomic layers was observed, probably as a result of flow of injected material along the perpendicular needle track as depicted in Figure 13. However, additional variables that could influence the outcome of this observational study are possible as summarized in Table 1. To determine whether our observations reflect the in vivo situation, further cadaver studies are warranted with more specimens, using a range of commercially available filler products, different angled approaches, and different gauge needles and cannulae. Ultimately, a larger cohort

is needed, in vivo, to make any kind of final conclusions regarding the safety, precision, or amount of backflow of cannulae and needles.

Finally, a very important conclusion that can be made based on the results of this observational study is that injecting with a sharp needle can potentially result in intra-vascular embolization, even when the needle is in constant contact with the periosteum (Figure 1D [white arrow] and Figure 12). Safety is improved when injecting on the periosteum with non-traumatic cannulae, but not guaranteed.

Supplementary Material

This article contains supplementary material located online at www.aestheticsurgeryjournal.com.

Disclosures

Dr van Loghem has worked as a consultant for Merz Aesthetics, Allergan, and Ipsen. Dr Humzah has worked as a consultant for Merz Aesthetics, Allergan, and Galderma. Prof Kerscher has worked as a consultant for Merz Aesthetics, Allergan and Galderma.

Funding

Filler products that were used in this study were supplied by Merz Aesthetics.

REFERENCES

1. Funt D, Pavicic T. Dermal fillers in aesthetics: an overview of adverse events and treatment approaches. *Clin Cosmet Investig Dermatol*. 2013;6:295-316.
2. Beer K, Beer J. Overview of facial aging. *Facial Plast Surg*. 2009;25(5):281-284.
3. Cosmetic surgery national data bank statistics. *Aesthet Surg J*. 2016;36(Suppl 1):1-29.
4. Van Loghem J, Yutskovskaya Y, Werschler P. Calcium hydroxylapatite: over a decade of clinical experience. *J Clin Aesthet Dermatol*. 2014;7:38-49.
5. Muhn C, Rosen N, Solish N, et al. The evolving role of hyaluronic acid fillers for facial volume restoration and contouring: a Canadian overview. *Clin Cosmet Investig Dermatol*. 2012;5:147-158.
6. Gierloff M, Stöhring C, Buder T, Gassling V, Açil Y, Wiltfang J. Aging changes of the midfacial fat compartments: a computed tomographic study. *Plast Reconstr Surg*. 2012;129(1):263-273.
7. Warren RJ, Aston SJ, Mendelson BC. Face lift. *Plast Reconstr Surg*. 2011;128(6):747e-764e.
8. Sadick NS, Manhas-Bhutani S, Krueger N. A novel approach to structural facial volume replacement. *Aesthetic Plast Surg*. 2013;37(2):266-276.
9. Greco TM, Antunes MB, Yellin SA. Injectable fillers for volume replacement in the aging face. *Facial Plast Surg*. 2012;28(1):8-20.
10. Gierloff M, Stöhring C, Buder T, Wiltfang J. The subcutaneous fat compartments in relation to aesthetically important facial folds and rhytides. *J Plast Reconstr Aesthet Surg*. 2012;65(10):1292-1297.
11. Lambros V. Observations on periorbital and midface aging. *Plast Reconstr Surg*. 2007;120(5):1367-1376; discussion 1377.
12. Sykes JM, Cotofana S, Trevidic P, Solish N, Carruthers J, Carruthers A, Moradi A, Swift A, Massry GG, Lambros V, Remington BK. Upper face: clinical anatomy and regional approaches with injectable fillers. *Plast Reconstr Surg*. 2015;136:204S-218S.
13. Grunebaum LD, Allemann IB, Dayan S, Mandy S, Baumann L. The risk of alar necrosis associated with dermal filler injection. *Dermatol Surg*. 2009;35:1635-1640.
14. Tansatit T, Apinuntrum P, Phetudom T. A cadaveric feasibility study of the intraorbital cannula injections of hyaluronidase for initial salvation of the ophthalmic artery occlusion. *Aesthetic Plast Surg*. 2015;39(2):252-261.
15. Kim DW, Yoon ES, Ji YH, Park SH, Lee BI, Dhong ES. Vascular complications of hyaluronic acid fillers and the role of hyaluronidase in management. *J Plast Reconstr Aesthet Surg*. 2011;64(12):1590-1595.
16. Zeichner JA, Cohen JL. Use of blunt tipped cannulas for soft tissue fillers. *J Drugs Dermatol*. 2012;11(1):70-72.
17. Fulton J, Caperton C, Weinkle S, Dewandre L. Filler injections with the blunt-tip microcannula. *J Drugs Dermatol*. 2012;11(9):1098-1103.
18. Funt D. Avoiding malar edema during midface/cheek augmentation with dermal fillers. *J Clin Aesthet Dermatol*. 2011;4:32-36.
19. Casabona G. Blood aspiration test for cosmetic fillers to prevent accidental intravascular injection in the face. *Dermatol Surg*. 2015;41:841-847.
20. Pavicic T. Complete biodegradable nature of calcium hydroxylapatite after injection for malar enhancement: an MRI study. *Clin Cosmet Investig Dermatol*. 2015;8:19-25.
21. Griepentrog GJ, Lemke BN, Burkat CN, Rose JG Jr, Lucarelli MJ. Anatomical position of hyaluronic Acid gel following injection to the infraorbital hollows. *Ophthal Plast Reconstr Surg*. 2013;29(1):35-39.
22. Sundaram H, Cassuto D. Biophysical characteristics of hyaluronic acid soft-tissue fillers and their relevance to aesthetic applications. *Plast Reconstr Surg*. 2013;132(4 Suppl 2):5S-21S.
23. Pilsl U, Rosmarin W, Anderhuber F. The premaxillary space: a location for filler injection? *Dermatol Surg*. 2014;40(3):301-304.
24. Batheja P, Sheihet L, Kohn J, Singer AJ, Michniak-Kohn B. Topical drug delivery by a polymeric nanosphere gel: Formulation optimization and in vitro and in vivo skin distribution studies. *J Control Release*. 2011;149(2):159-167.